

# Peripheral Ulcerative Keratitis After Trabeculectomy in a Patient With Rheumatoid Arthritis

*Dimitris Papaconstantinou, MD,\* Gerasimos Georgopoulos, MD,\* George Kalantzis, MD,\* Augustinos Krassas, MD,\* and Ilias Georgalas, MD†*

**Purpose:** To report the unusual occurrence of peripheral ulcerative keratitis, 10 days after trabeculectomy in a 35-year-old patient with rheumatoid arthritis (RA).

**Methods:** Observational case report.

**Results:** A 35-year-old patient with RA and secondary Sjögren disease underwent an uneventful fornix-based trabeculectomy. Ten days after surgery, slit-lamp examination revealed a peripheral corneal ulcer extending from 5- to 7-o'clock positions with a surrounding inflammatory infiltrate and adjacent conjunctival injection. The ulcer was treated with systemic and topical steroids, antibiotic eyedrops, artificial tears, and a bandage soft contact lens. Since then, corneal re-epithelialization started and the patient's symptoms subsided. The ulcer improved steadily within 2 months while the patient used a soft contact lens. The ulcer did not reoccur in the 18 months follow-up while the patient remained under systemic treatment.

**Conclusion:** This report highlights the importance of careful examination and close postoperative follow-up in patients with RA undergoing any intraocular surgery, to diagnose a possible development of peripheral ulcerative keratitis. Although the incidence is rare, prompt diagnosis of the peripheral ulceration is essential because if untreated it may seriously affect patient's vision.

**Key Words:** peripheral ulcerative keratitis, rheumatoid arthritis, trabeculectomy

(*Cornea* 2009;28:111–113)

## INTRODUCTION

Peripheral ulcerative keratitis (PUK) is a rare inflammatory disease of the cornea, usually manifested in systemic immune-mediated diseases, and rheumatoid arthritis (RA) is one of the most common underlying entities.<sup>1</sup> The occurrence of sterile corneal ulcers after cataract surgery in patients with

known collagen vascular disease has been well documented in the literature.<sup>2–6</sup>

We describe a patient with RA and secondary Sjögren disease who presented with PUK within 10 days after uneventful trabeculectomy, which to the best of our knowledge has never been reported before.

## CASE REPORT

A 35-year-old woman was referred to Glaucoma Service in April 2006. She gave a 7-year history of seropositive, erosive RA and secondary Sjögren syndrome, well controlled under treatment with leflunomide (20 mg od) and prednisolone (5 mg od) for the last 6.5 years. Since 2002, the patient had been diagnosed with keratoconjunctivitis sicca and was under treatment with artificial tears. In 2004 and 2005 she underwent uncomplicated phacoemulsification for steroid-induced cataract in the right eye (RE) and left eye (LE), respectively.

On examination, her best-corrected-visual-acuity (BCVA) was 1/20 RE, 20/20 LE and intraocular pressure (IOP) measured at 30 mm Hg RE and 12 mm Hg LE. Anterior segment examination of both eyes showed corneal filaments, low tear meniscus, and papillary conjunctivitis. Fundoscopy revealed severe glaucomatous cupping (C/D ratio 0.8) in RE with corresponding scotomas in the Humphrey visual field test.

Initially the patient was administered g. latanoprost od, g. brimonidine bid, and a fixed combination of g. dorzolamide–timolol bid. However, the IOP was insufficiently controlled and surgical intervention was suggested to the patient.

Three months later, an RE fornix-based trabeculectomy was performed under local anesthetic. There were no intraoperative complications, and the patient was administered a fixed combination of g. chloramphenicol–dexamethasone qid and g. atropine 1% tid. One day after surgery, examination was unremarkable (Fig. 1). However, 10 days later, the patient presented with pain, a nonspecific foreign body sensation, and a watering eye. BCVA was 1/60 RE and IOP 13 mm Hg. Slit-lamp examination revealed a peripheral corneal ulcer extending from 5- to 7-o'clock positions with a surrounding inflammatory infiltrate and adjacent conjunctival injection. There were +2 anterior chamber cells without fibrin threads (Fig. 2).

Corneal cultures and scrapings were taken using the blunt end of a surgical blade and topical anesthesia. The smears were stained with hematoxylin and eosin, Giemsa, and Wright and Ziehl–Nielsen stains. The culture media used blood, chocolate and Sabouraud's dextrose agars, McConkey agar, nonnutritive agar for acanthamoeba, and Schaedler's broth. Viral cultures and blood serologies for herpes simplex virus (HSV), Varicella zoster virus, hepatitis B virus (HBV), and hepatitis C virus (HCV) were also obtained. All cultures were negative for any infectious etiology.

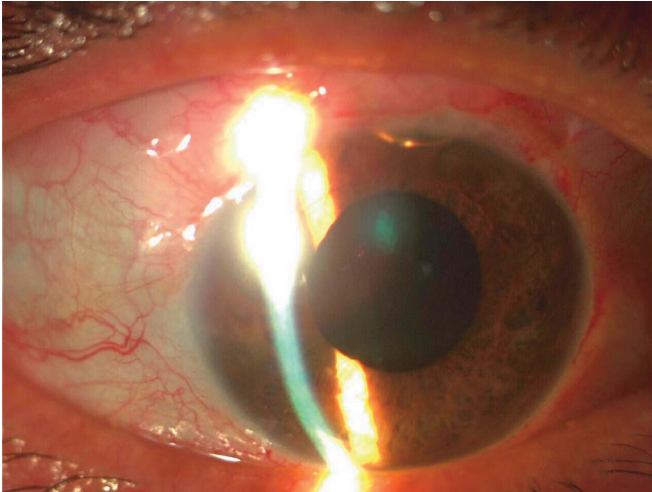
Rheumatology examination was unremarkable, and blood workup disclosed a normal complete blood count (hemoglobin:

Received for publication February 27, 2008; revision received June 4, 2008; accepted June 8, 2008.

From the \*Department of Ophthalmology, "G. Gennimatas" Hospital, University of Athens, Athens, Greece; and †Department of Ophthalmology, "G. Gennimatas" Hospital, NHS, Athens, Greece.

Reprints: Ilias Georgalas, MD, Department of Ophthalmology, "G. Gennimatas" Hospital, NHS, 59 Chrysanthemon Strasse, P. Pshychico, 15452 Athens, Greece (igeorgalas@yahoo.com).

Copyright © 2008 by Lippincott Williams & Wilkins

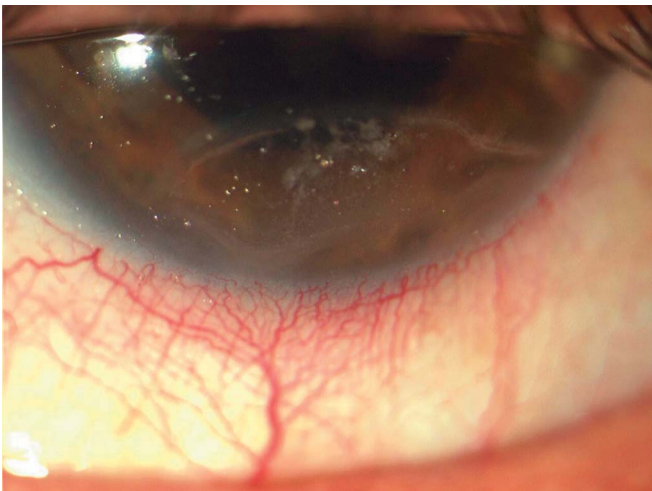


**FIGURE 1.** First postoperative day after trabeculectomy, the cornea is clear. Note the small residual air bubble in the anterior chamber at 12-o'clock position.

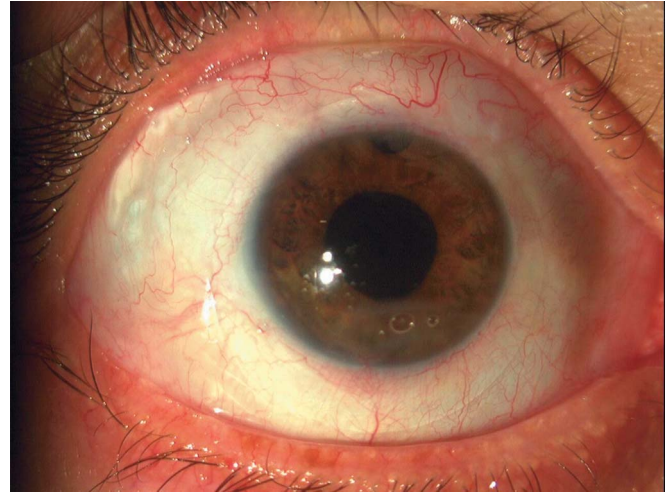
12.3 mg/dL; hematocrit: 38.5%; white blood cells: 8600/mm<sup>3</sup>), a normal Erythrocyte sedimentation rate (ESR) (11 mm/hour), a normal C-reactive protein (2.1 mg/L), and a positive rheumatoid factor (241 IU/mL).

The patient was administered initially an intravenous bolus of methylprednisolone 250 mg and then was placed on oral prednisolone 32 mg od. Dexamethasone and ciprofloxacin eyedrops were also administered tid, and frequent lubrication with artificial tears and gel was done. Two days later there was little improvement, and a bandage soft contact lens was applied to the RE. Two weeks later minimal conjunctival injection remained, no further stromal ulceration occurred and total re-epithelialization of the ulcer was evident.

At the 2-month follow-up (Fig. 3), BCVA was 1/20 RE and the contact lens was removed. The patient remained on prednisolone tablets (32 mg once a day) and had no recurrence of corneal melt during the next 18 months.



**FIGURE 2.** Ten days after surgery. A peripheral corneal ulcer extends between the 5- and 7-o'clock positions with a surrounding inflammatory infiltrate and adjacent conjunctival injection.



**FIGURE 3.** Two months after the application of a soft contact lens, total re-epithelialization of the ulcer was evident and no further ulceration occurred.

## DISCUSSION

PUK can occur in a variety of ocular and systemic conditions including infections, lid abnormalities, dermatological disorders, and connective tissue disorders.<sup>7</sup> It usually occurs inferiorly in the corneas of the patients with long-standing RA.<sup>1</sup> It is most often contiguous with adjacent scleritis, but it may occur as an isolated finding.<sup>8</sup> PUK, without appropriate treatment, may be associated with a poor visual outcome and a mortality of up to 30%.<sup>1,9</sup>

PUK, with or without associated necrotizing scleritis, has been documented after cataract surgery in patients with RA.<sup>1,5</sup> Sclerocorneal ulcerations most commonly occur at the incision site, and the posterior lip is the main area of involvement.<sup>10</sup> However, the pathogenesis of PUK after cataract surgery has not been fully elucidated. Díaz-Valle et al<sup>11</sup> suggested that postsurgical necrotizing sclerocorneal ulceration is relevant to the disruption of episcleral and perforating scleral vessels during surgery, as it leads to entrapment of the immune complexes and thus initiation of an inflammatory response. Hemady et al<sup>12</sup> have postulated that aqueous tear insufficiency is a contributing factor in the development of PUK. The surgical denervation of the cornea and the use of topically administered medications that cause epithelial toxicity have been considered to be predisposing factors for the development of PUK.<sup>4</sup> Additionally, Villani et al,<sup>13</sup> in a study with confocal microscope, identified several alterations of cell activity in the cornea of the patients with RA. These inflammatory, neurodegenerative, and regenerative alterations may be associated with the severity of ocular surface disease and the development and severity of PUK.<sup>13</sup>

In our case the PUK occurred a few days after an uncomplicated fornix-based superior trabeculectomy. There was no associated scleritis, and the infiltrate was confined to the corneal stroma at the opposite site of the scleral flap. No traction suture had been placed nearby the corneal melt site, and no surgical maneuvers had caused any corneal

trauma. We postulate that in our patient with RA, the severe xerophthalmia due to secondary Sjögren disease and the postoperative administration of 2 eyedrops (g. atropine 1% tid and g. chloramphenicol–dexamethasone qid) facilitated the access of the rheumatoid factor and the immune complexes into the stroma by disrupting the immune privilege of the stroma. It should be also taken into consideration that the interference of the surgical wound with the lid motility may have contributed to incomplete lid closure and this in turn may have augmented the xerophthalmia and subsequently facilitated the development of the ulcer.

Our patient had a typical presentation site of PUK (inferior aspect of the cornea) and was treated with systemic and topical steroids, antibiotic eyedrops, artificial tears, and efficient lubrication. Initially there was little improvement, and thus, the application of a bandage soft contact lens was decided. Since then, corneal re-epithelialization started and the patient's symptoms subsided. The ulcer improved steadily within 2 months of follow-up while the patient used a soft contact lens, which was probably the catalytic therapeutic intervention. The ulcer did not recur in the follow-up treatment with the patient on systemic treatment.

Our case illustrates the rare but possible occurrence of PUK after an uncomplicated trabeculectomy in a well-controlled rheumatoid patient, which to the best of our knowledge has never been reported before. It also highlights that in patients with RA, PUK may occur after any intraocular surgery and not necessarily close to the incision site. Although the incidence is rare, careful examination and close postoperative follow-up maybe necessary in patients with RA undergoing not only cataract but also glaucoma surgery, to promptly diagnose the development of PUK which if not

aggressively treated may have devastating complications on patient's vision.

## REFERENCES

1. Malik R, Culinane AB, Tole DM, et al. Rheumatoid keratolysis: a series of 40 eyes. *Eur J Ophthalmol.* 2006;16:791–797.
2. Galor A, Thorne JE. Scleritis and peripheral ulcerative keratitis. *Rheum Dis Clin North Am.* 2007;33:835–854, vii.
3. Salamon SM, Mondino BJ, Zaidman GW. Peripheral corneal ulcers, conjunctival ulcers, and scleritis after cataract surgery. *Am J Ophthalmol.* 1982;93:334–337.
4. Maffett MJ, Johns KJ, Parrish CM, et al. Sterile corneal ulceration after cataract extraction in patients with collagen vascular disease. *Cornea.* 1990;9:279–285.
5. Akpek EK, Demetriades A, Gottsch JD. Peripheral ulcerative keratitis after clear corneal cataract extraction (1). *J Cataract Refract Surg.* 2000; 26:1424–1427.
6. Jones RR, Maguire LJ. Corneal complications after cataract surgery in patients with rheumatoid arthritis. *Cornea.* 1992;11:148–150.
7. Bhatt PR, Lam FC, Roberts F, et al. Peripheral ulcerative keratitis due to a 'long lost' hard contact lens. *Clin Exp Ophthalmol.* 2007;35:550–552.
8. Shiuey Y, Foster CS. Peripheral ulcerative keratitis and collagen vascular disease. *Int Ophthalmol Clin.* 1998;38:21–32.
9. Foster CS, Forstot SL, Wilson LA. Mortality rate in rheumatoid arthritis patients developing necrotizing scleritis or peripheral ulcerative keratitis. Effects of systemic immunosuppression. *Ophthalmology.* 1984;91: 1253–1263.
10. O'Donoghue E, Lightman S, Tuft S, et al. Surgically induced necrotizing sclerokeratitis (SINS)—precipitating factors and response to treatment. *Br J Ophthalmol.* 1992;76:17–21.
11. Diaz-Valle D, Benitez del Castillo JM, Castillo A, et al. Immunologic and clinical evaluation of postsurgical necrotizing sclerocorneal ulceration. *Cornea.* 1998;17:371–375.
12. Hemady R, Chu W, Foster CS. Keratoconjunctivitis sicca and corneal ulcers. *Cornea.* 1990;9:170–173.
13. Villani E, Galimberti D, Viola F, et al. Corneal involvement in rheumatoid arthritis: an in vivo confocal study. *Invest Ophthalmol Vis Sci.* 2008;49: 560–564.